

Congenital Hyponychia of the Hands with Lymphangiectases: A New Entity?

ANGEL FERNANDEZ-FLORES¹, JOSE ANTONIO MANJON²

ABSTRACT

We present a case of 58-year-old woman with congenital hyponychia of the ten fingers and oedema of the fingertips as the only cutaneous alterations. There was no associated systemic condition or additional ectodermal abnormality. The biopsy showed lymphangiectases mainly confined to the papillary dermis but also in the reticular dermis. We propose the designation “congenital hyponychia of the hands with lymphangiectases” for this apparently not previously described condition.

Keywords: Lymphangiectasy, Nail dystrophy, Yellow nail syndrome

CASE REPORT

A 58-year-old woman presented to the dermatology consultancy searching for advice for a problem in all of the fingers that she had had “since childhood.” She did not describe pain but complained that the tips were hardened and swollen. Her medical history was unremarkable. The examination showed edematous swelling and hardening of all the tips of the fingers of both hands with desquamation on the perionychia [Table/Fig-1]. This was accompanied by thinning of the fingernail plates, which appeared dystrophic and delustrated with onychoschizia and longitudinal striations. The patient had never cut her nails in her entire life. Koilonychia was present in some of the plates. Nail plates did not show discoloration, and lunulae were preserved. Toenails, teeth, and hair were normal. She had no other cutaneous pathology. There was no oedema of the limbs or palpable adenopathies. When specifically questioned, the patient denied any respiratory symptoms or sinusitis. Laboratory tests (including hepatic and renal parameters and lipidic profile) were all normal. Antinuclear antibodies as well as anti SCL-70 was negative. Radiographic studies of the thorax, both hands, and the sinuses were normal. A biopsy of one of the fingertips was performed.

The biopsy showed moderate oedema of the reticular dermis [Table/Fig-2]. There were no mucin deposits in the dermis (stainings with Alcian Blue and colloidal iron were negative). The most remarkable finding was the evidence of prominent lymphangiectases, which gave the biopsied area a “moth-eaten” appearance [Table/Fig-2]. Some lymphangiectases were present in the reticular dermis, but they were mainly found in the papillary dermis [Table/Fig-3]. Some of the lymphangiectases showed mild fibrotic reinforcement of their walls [Table/Fig-4]. The endothelia of the lymphangiectases expressed D2-40 in the immunohistochemical study [Table/Fig-5].

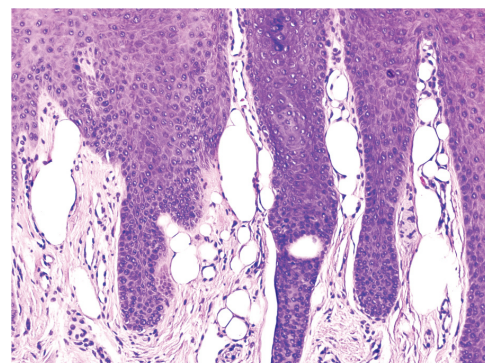
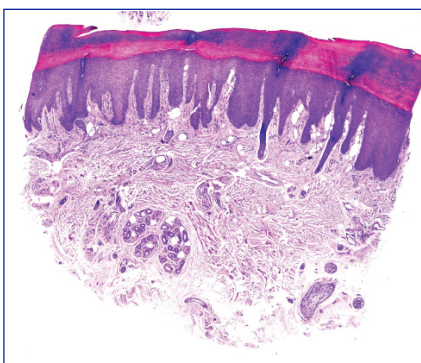
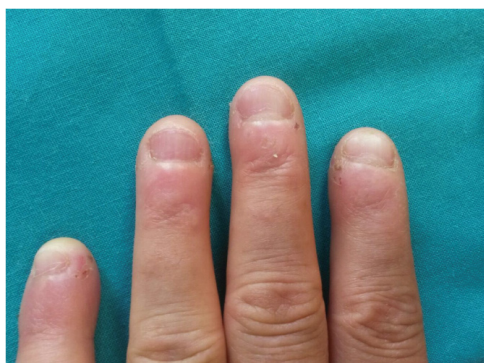
The patient was questioned regarding presentation of the same features in any member of her family, which she denied. She specifically remembered that her parents did not have any nail alteration. The patient has one son and two daughters, and she confirmed that none of them presented any nail alterations.

DISCUSSION

We report one case of hyponychia of the hands that does not fit the requirements of any entity reported so far. For instance, it does not fit the diagnosis of congenital hyponychia. Cases of congenital hyponychia usually involve both fingernails and toenails. Moreover, they are commonly associated with skeletal, limb, and ectodermal abnormalities, none of which were present in our patient.

Our cases did not meet either of the requirements for yellow nail syndrome, which was described in 1964 [1]. Yellow nail syndrome is characterized by thickened, yellow, slow-growing nails, which are usually curved in a convex way. Other colour changes (abnormally pale or green colouring) in the nails can also be present in yellow nail syndrome, and onycholysis is also a feature [1]. The other clinical features of yellow nail syndrome are lymphoedema and pleural effusion. Bronchiectases and rhinosinusitis have also been considered as part of the syndrome [2]. Our case did not present any of these features; the nails were not thickened, and koilonychia was present, which is not a feature of yellow nail syndrome.

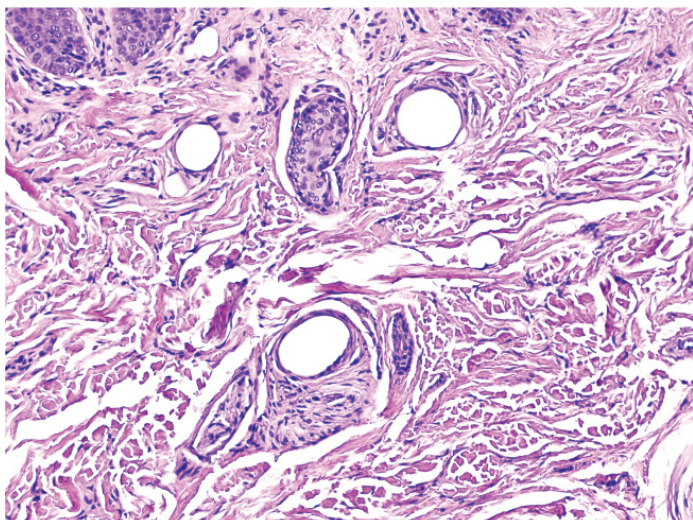
Our case did not fit either of the features of pachydermodactyly due to repetitive motion, which has been associated with certain manual tasks such as poultry processing [3]. The latter is a form of fibromatosis that presents clinically as symmetrical swelling of the tissues surrounding the proximal interphalangeal joints [3]. Histopathological examination shows thickening of the dermis with



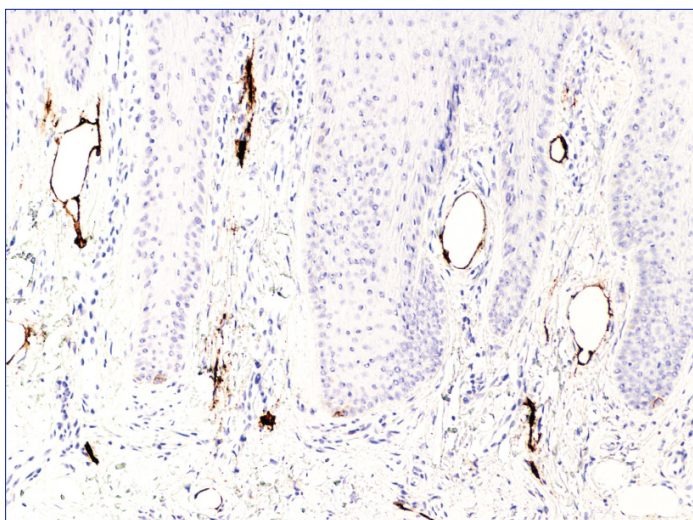
[Table/Fig-1]: The patient presented with oedema and hardening of all fingertips. Thinning of the fingernail plates with onychoschizia was present

[Table/Fig-2]: The biopsy from the fingertip showed lymphangiectases mainly confined to the papillary dermis (Hematoxylin-eosin, X 2.5)

[Table/Fig-3]: High magnification of the lymphangiectases (Hematoxylin-eosin, x 40)



[Table/Fig-4]: Some of the lymphangiectasies were also present in the reticular dermis. Showing a fibrotic reinforcement of their walls (Hematoxylin-eosin, x10)



[Table/Fig-5]: An immunohistochemical study demonstrated immunopositivity of D2-40 by the endothelia of the lymphangiectasies (D2-40, podoplanin)

an increased amount of fibroblasts and collagen types III and V [4]. Neither the clinical nor the histopathological features matched the ones present in our case. Other causes of ungula dystrophia were also excluded in our patient: a vitaminic or nutritional deficiency was excluded by the laboratory analyses, and a concomitant cutaneous inflammatory condition, such as psoriasis, atopic dermatitis, lichen planus, or alopecia areata was also ruled out. The evidence of lymphangiectasies in the fingertips in our case deserves a comment. Dilated lymphatic capillaries have been described in pleural biopsies of patients with yellow nail syndrome and pleural effusion [5]. Also, De Coste et al., described “numerous ecstatic, endothelium-lined vessels” in the bed and matrix of a nail biopsy in a case of yellow

nail syndrome [6]. In fact, lymphatic malformations have been suggested as a pathogenic factor for some of the manifestations of certain syndromes that present nail dystrophy, such as yellow nail syndrome [1]. In the latter, lymphography has sometimes shown diffusely hypoplastic lymphatic vessels [7]. It is not yet known whether peripheral lymphoedema can explain the nail dystrophy in yellow nail syndrome [7]. Interestingly, although lymphangiographic data from cases of yellow nail syndrome suggests lymphatic hypoplasia, dilatations, and an extensive collateral lymphatic network, some authors have remarked that such characteristics are difficult to reconcile with the improvement of peripheral oedema present over time in some cases [7]. An alternative hypothesis is a functional defect of the lymphatic vessels. In our case, we identified lymphangiectasies, which is also more in consonance with a functional lymphatic abnormality rather than a malformation. The fact that such lymphangiectasies were located mainly in the papillary dermis and the superficial reticular dermis is evidence against a lymphatic obstruction with impediment of lymphatic drainage.

Wang et al., have recently described six cases of lymphatic malformations clinically characterized by swelling of the digits [8]. However, in their cases, only one finger (two cases), multiple fingers (three cases), or a single toe (one case) were involved. Moreover, the fingertips were not affected. Histopathological examination of their cases showed a lymphatic growth with features of malformation with slit-like, flat, round, or angular-shaped vessels [8]. These features are obviously not the ones present in our case, in which the alterations were mainly seen at the fingertips of all fingers and were mainly characterized by plethoric, dilated, and non-malformed lymphatic vessels.

CONCLUSION

We present a case with clinical and histopathological features that seem not to have been described before, and we propose the designation “hyponychia of the hands with lymphangiectasies” to refer to this condition.

REFERENCES

- [1] Samman PD, White WF. The “Yellow Nail” Syndrome. *Br J Dermatol*. 1964;76:153-57.
- [2] Hershko A, Hirshberg B, Nahir M, Friedman G. Yellow nail syndrome. *Postgrad Med J*. 1997;73:466-68.
- [3] Sagransky MJ, Pichardo-Geisinger RO, Munoz-Ali D, Feldman SR, Mora DC, Quandt SA. Pachydermodactyly from repetitive motion in poultry processing workers: a report of 2 cases. *Arch Dermatol*. 2012;148:925-28.
- [4] Ye S, Chen SL, Dong YQ, Lin F, Guo Q, Bao CD. Pachydermodactyly: six new cases from China. *J Clin Rheumatol*. 2005;11:72-75.
- [5] Solal-Celigny P, Cormier Y, Fournier M. The yellow nail syndrome. Light and electron microscopic aspects of the pleura. *Arch Pathol Lab Med*. 1983;107:183-85.
- [6] De Coste SD, Imber MJ, Baden HP. Yellow nail syndrome. *J Am Acad Dermatol*. 1990;22:608-11.
- [7] Maldonado F, Tazelaar HD, Wang CW, Ryu JH. Yellow nail syndrome: analysis of 41 consecutive patients. *Chest*. 2008;134:375-81.
- [8] Wang L, Gao T, Wang G. Cutaneous lymphatic malformation characterized by swelling of digits: a report of six cases. *J Cutan Pathol*. 2014;41:451-56.

PARTICULARS OF CONTRIBUTORS:

1. Faculty, Department of Cellularpathology, Hospital El Bierzo, Ponferrada, Spain.
2. Faculty, Department of Dermatology, Hospital El Bierzo, Ponferrada, Spain.

NAME, ADDRESS, E-MAIL ID OF THE CORRESPONDING AUTHOR:

Dr. Angel Fernandez-Flores,
Servicio De Anatomía Patológica, Hospital El Bierzo, Medicos sin Fronteras 7, 24411, Ponferrada, Spain.
E-mail : dermatopathonline@gmail.com

FINANCIAL OR OTHER COMPETING INTERESTS: None.

Date of Submission: **Oct 11, 2014**
Date of Peer Review: **Dec 07, 2014**
Date of Acceptance: **Feb 11, 2015**
Date of Publishing: **Mar 01, 2015**